Hernia
https://doi.org/10.1007/s10029-019-01972-2

REVIEW

Pure tissue repairs: a timely and critical revival

R. Bendavid[1] · M. Mainprize[1] · Vladimir Iakovlev[2]

Received: 23 April 2019 / Accepted: 4 May 2019

Abstract
"The majority of hernias can be satisfactorily repaired by using the tissues at hand. The use of mesh prosthesis should be restricted to those few hernias in which tension or lack of good fascial structures prevents a secure primary repair. This group includes large direct inguinal hernias and incisional hernias in which the defect is too large to close primarily without undue tension. Most recurrent hernias, because of this factor are best repaired with mesh prosthesis". These words, penned in 1960 by Francis Usher have reconfirmed what had been a mantra of the Shouldice Hospital (Usher in 81:847–854, 1960). The Shouldice Hospital has specialized in the treatment of abdominal wall hernias since 1945. It has, since its beginning, insisted on the fact that a thorough knowledge of anatomy coupled with large volumes of surgical cases would lead to unparalleled expertise. It was Cicero who taught us that "Practice, not intelligence or dexterity, will win the day"! Since the seminal contribution of Bassini (1844–1924), there have been no less than 80 procedures imitating his inguinal herniorrhaphy and much more since the introduction of mesh and mesh devices (Iason in Hernia. The Blakiston Company, Philadelphia, pp 475–604, 1940). All have failed to some extent and it appears that the common denominator for these failures was the inability to understand the importance of entering the preperitoneal space. Only Shouldice and McVay (Lotheissen, Narath) realized the shortcoming and have continued to thrive as a successful procedure. Entering the preperitoneal space eliminates any temptation to plicate the posterior inguinal wall, a layer normally deficient in direct inguinal hernias, but it also allows the identification of muscle layers rectus, transversus and internal oblique muscles which will go to reconstruct the posterior inguinal wall, without tension as reported by Schumpelick (Junge in 7(1):17–20, 2003).

Keywords Pure tissue repair · Inguinal hernias · Polypropylene mesh · CPIP (chronic post-inguinal herniorrhaphy pain)

Introduction

"The majority of hernias can be satisfactorily repaired by using the tissues at hand. The use of mesh prosthesis should be restricted to those few hernias in which tension or lack of good fascial structures prevents a secure primary repair. This group includes large direct inguinal hernias and incisional hernias in which the defect is too large to close primarily without undue tension. Most recurrent hernias, because of this factor are best repaired with mesh prosthesis". These words, penned in 1960 by Francis Usher have reconfirmed what had been a mantra of the Shouldice Hospital [1].

The Shouldice Hospital has specialized in the treatment of abdominal wall hernias since 1945. It has, since its beginning, insisted on the fact that a thorough knowledge of anatomy coupled with large volumes of surgical cases would lead to unparalleled expertise. It was Cicero who taught us that "Practice, not intelligence or dexterity, will win the day".

Since the seminal contribution of Bassini (1844–1924), there have been no less than eighty procedures imitating his inguinal herniorrhaphy and much more since the introduction of mesh and mesh devices [2]. All have failed to some extent and it appears that the common denominator for these failures was the inability to understand the importance of entering the preperitoneal space. Only Shouldice and McVay (Lotheissen, Narath) realized the shortcoming and have

The article is part of the Topical Collection "Forum on primary monolateral uncomplicated inguinal hernia".

Vladimir Iakovlev consulted for pathology.

✉ R. Bendavid
rbendavid@sympatico.ca

1 Department of Surgery, Shouldice Hospital, Thornhill, ON, Canada

2 Department of Pathology, University of Toronto, Toronto, Canada

Published online: 20 May 2019

continued to thrive as a successful procedure. Entering the preperitoneal space eliminates any temptation to plicate the posterior inguinal wall, a layer normally deficient in direct inguinal hernias, but it also allows the identification of muscle layers rectus, transversus and internal oblique muscles which will go to reconstruct the posterior inguinal wall, without tension as reported by Schumpelick [3].

Historical synopsis

It is an unfortunate rumor, unfounded, that the Shouldice Hospital is perceived as an "anti-mesh" institution. Nothing can be further from the truth.

The first ever mesh devices used in hernia repairs, made of polypropylene, were conceived and designed at this hospital in 1986 and 1989 [4, 5].

The first double mesh (polypropylene/ePTFE) which went on to become Composix® saw the light of day in the same institution and was published in the first issue of HERNIA in 1997 [6].

The concept of "tailored approach" so popular nowadays originated at this institution and was already in print in 1992 with its own set of recommendations [7, 8]. This concept predicted where and when mesh ought to be introduced judiciously, in selected patients, with specific pathology, rather than blindly in all abdominal wall hernia sufferers.

In 1994, the first textbook ever on the use of various meshes in abdominal wall hernia surgery was published at the Shouldice Hospital and elicited a laudatory letter from Lloyd M. Nyhus [9].

For good measure, we threw in the first description and report ever of "dysejaculation", rare with pure tissue repairs (0.04%) likely due to scarring and distortion but more common when the spermatic cord in open mesh procedures or the denuded vas deferens in the laparoscopic approach, comes in contact with mesh, thus initiating a chronic erosive mechanism (3.1%), an 80-fold increase!

Our last three publications were studies on: (a) polypropylene degradation, a material still erroneously labeled as inert, (b) neo-innervation of mesh and etiology of pain and (c) evidence of mesh erosion into the thickness of the spermatic cord [10–12]. Our colleagues from the Danish Hernia Database have added a new clinical entity: "groin and testicular pain during sexual activity" with an incidence of 10.9% [13]. Two more papers are being readied for publications on mesh explants for pathological reasons.

The description of the venous circle within the Space of Bogros [14] also described originally at our hospital and which, through further research in Brazil, was found to connect the right and left [15] groins was a discovery that stunned John Skandalakis who readily incorporated it into his surgical anatomy.

To expand the academics of hernia anatomy, we went to Paris in an attempt to obtain originals of the textbook by Henri Fruchaud and the Thesis of Bogros both of which were translated into English and expanded the scope of an anatomy which had laid dormant since Bassini. We all have René Stoppa to thank for prodding us into the works of the giants who preceded us and to bring them, so unselfishly, to the hernia community.

Review of past results in pure tissue repair

Unfortunately, one has to go back 20 years and more to gather extensive statistics on what used to be considered the "gold standard" in hernia repair: the Shouldice operation. The recurrence rate as reported by notable surgeons of the time were as follows: Shearburn (0.2%), Volpe (0.2%), Wantz (0.3%), Myers (0.7%), Devlin (0.8%), Flament (0.9%), Wantz in a different series (1.0%), Shouldice Hospital (1.46%), Moran (2.0%), Berliner (2.7%) [16] and Zimmerman (0.7%) after an 8-year follow-up [17]. Those results were from series ranging from 121 to 3454 patients with follow-up of 1–20 years. Schumpelick et al. have "failed to see any evidence for the hypothesis that higher inguinal tensile strength induced by the Shouldice repair leads to an elevated level of post-operative pain" [3, 18]. No studies that we are aware of have led to the establishment of the so-called "tension free repair" and measuring its tension against pure tissue repair. Skeletal muscle is known for its ability to adapt to new strains, directions and stresses thus explaining the conclusion of Schumpelick [19, 20]. Who has analyzed the possibility that perhaps the shrinkage of a mesh to 50–60% of its original size does not contribute to a higher and more rigid tension than pure tissue repairs?

Brief but robust review of the current literature

With a resolute spirit, we have searched for a number of publications which would be beyond the pale influence by the industry, guidelines which have not been vetted by a blinded, peer review panel. Not an easy search!

We succeeded in ferreting out three such studies which provided volume, objectivity and integrity. One such study covers recurrence in hernia surgery from the Mayo Clinic, which confirmed that meshes have not improved the incidence of recurrences. The Mayo paper effectively debunked the myth that mesh is a panacea. The other two publications were studies from ICES (the Institute for Clinical Evaluation Sciences) which is the statistical arm of the University

of Toronto, with more than 200 full time statisticians, and is considered the finest department in its discipline [21–23].

Beginning with the publication of Brittany L. Murphy, Keith Paley et al. from the Mayo Clinic, their efforts stand as a paramount, sound, objective, now classic analysis of 317,636 patients from three sources: the Premier Database (127,908 patients; ACS-NSQIP, 180,512 patients and the Mayo Clinic's own patients registry (9216 patients). The resulting recurrence rates:

1. Premier Database: September 2010–September 2015 (127,908 patients).
   Men: 10.5–12.8%. Women: 6.5–6.7%.
2. ACS-NSQIP. January 2005–December 2014. (180,512 patients).
   Men: 10.5–11.2%. Women: 6.2–7.1%.
3. Mayo Clinic Registry: 2005–2014 (9216 patients).
   Men: 11.5–13.3%. Women 1.3–12.0%.

It would appear that whomever cannot do a pure tissue repair may have difficulties doing mesh-based repairs as well!

On the issue of groin hernias being treated with mesh or a pure tissue repair, ICES and the University of Toronto published what has been hailed as the most seminal paper ever on the effectiveness of a pure tissue repair method. There were two papers.

In the first paper, authored by Atiqa Malik, David Urbach et al. and with the help of ICES (Institute for Clinical Evaluation Sciences) reviewed 235,192 patients over a period of 14 years plus an additional 2 years to address year 14. All necessary statistical information was extracted from the database of the government health care system. The government, being the sole provider and payor of medical/surgical services for the people of Ontario, Canada, keeps the most thorough registry of all medical and surgical activity in the province and the relevant data are released only to ICES. The collected data are not available to the industry nor to an individual surgeon but only to ICES and the University of Toronto surgeon–scientists.

All the hospitals in Ontario, except for Shouldice Hospital, handled 170,065 patients or 72.3% of the patient population in that period of 14 years. The Shouldice hospital managed the remainder of 65,127 patients or 27.7% of all hernia repairs in the province of Ontario in this giant cohort. All patients were 18–90 years of age, median age 55 years, all had a primary inguinal hernia; men accounted for 90% and females for 10% of the cohort.

The hospitals which handled the larger group of 170,065 patients were divided into four groups depending on the yearly volume of hernia surgery within that hospital.

To summarize the end results: for each hospital group, the age standardized incidence of recurrence was 5.21%, 5.63%, 4.90% and 4.79%. For the Shouldice Hospital which was considered as a single entity because of the homogeneity of the surgical technique and the high number of surgeries per surgeon, the age standardized incidence of recurrence was 1.15%.

Subsequent to the release of the Malik and Urbach paper, we calculated that within that same time frame, at the Shouldice Hospital, a mesh repair of a groin hernia was carried out in 1.49% of all their patients and mostly for femoral hernias.

Fruchaud himself, in his unique and memorable textbook on hernia anatomy stated: "…in young adults, as in children, removal of the sac alone certainly yields better results than the Bassini repair…" of less than 3% [24].

The third paper was also issued from the University of Toronto a year later and was presented at the Scientific Session of the American College of Surgeon. The review, again with the help of ICES, covered 109,106 patients over a period of 9 years and 9 months. The distribution was as follows: laparoscopic 13,638 patients (12.5%); open without mesh: 15,602 (14.3%) and open with mesh: 79,866 (73.2%). The reported recurrence rates were for laparoscopic approach: 3.0%, for open without mesh 3.2% and for open with mesh: 1.7%. The flaw in this article was that, since all the data were obtained from the provincial government database, the authors did not include the 61,331 operations carried out at the Shouldice Hospital in that same period of time! Upon contacting the lead author, she stated that the Shouldice results were not "generalizable". Had the Shouldice numbers been added, the combined recurrence rate for the open without mesh repairs would have been 1.5%, since we knew that the recurrence rate of the Shouldice repair from the previous and larger study had been 1.15%. This implies that for the class of patients considered: primaries, 18–90 year old, a pure tissue repair is more effective than any other method with mesh. Since the majority of groin hernias are primaries, perhaps they should all be done by the simplest, safest and least costly method. All that is needed is a refresher course on the dissection of the groin.

Pain, the game changer as a complication of hernia surgery nowadays

Chronic post-inguinal herniorrhaphy pain has become a significant deciding factor in planning hernia surgery today. While the statistics of the Herniasurge International Guidelines reveal an incidence of 12%, they are the most conservative among the reports of the last 15–20 years [25]. It is timely to recall that an analysis by < guidelinewatch.de > which assesses transparency and independence from industry found that only 11% of 165 guidelines were rated

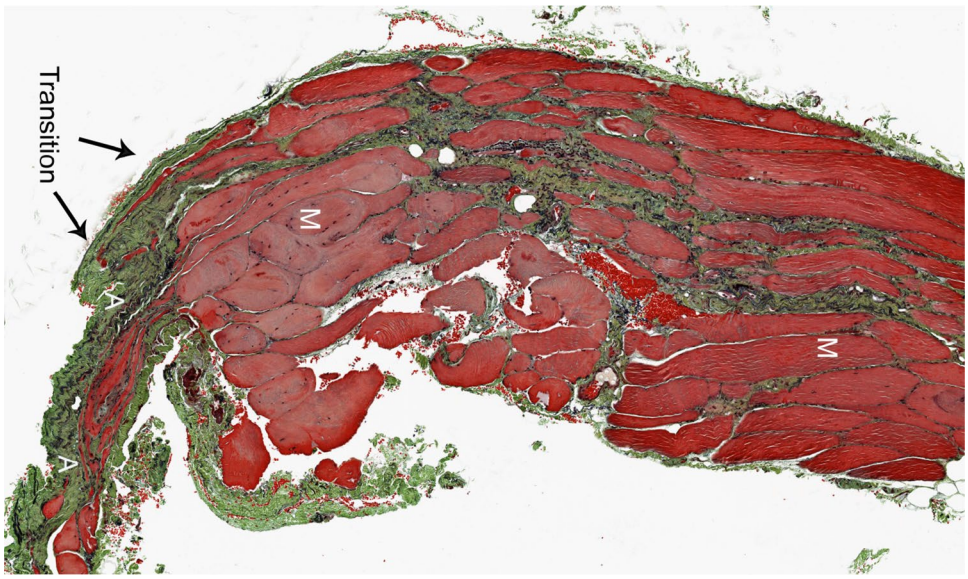

Fig. 1 Transition of abdominal muscle (M) into aponeurosis at the level of the groin. A Movat elastic stain, cropped image of a full image scan with magnification approximately equivalent to × 10 objective. Striated muscle (M) stains red, collagenous fibrous tissue including aponeurosis (A) stains green. Note that the transition is relatively abrupt. The muscle contains very little collagen between muscle fibers (color figure online)

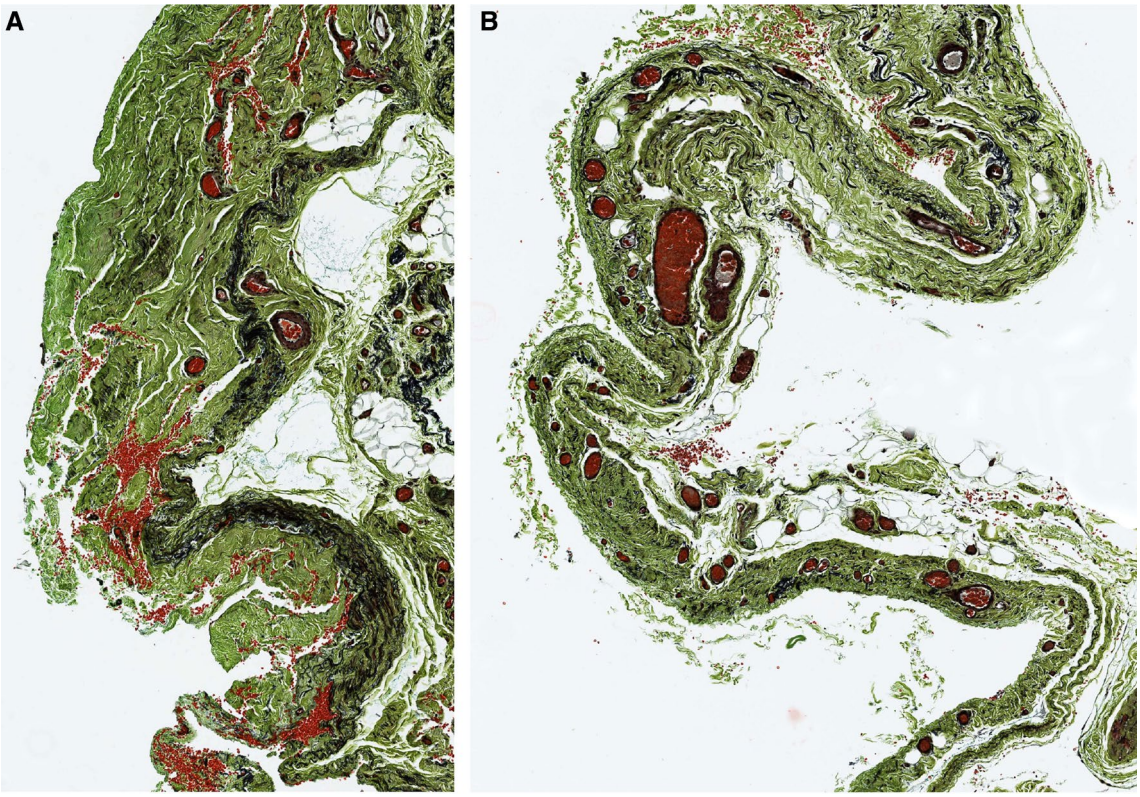

Fig. 2 Posterior wall, normal (**a**) and from a hernia sac (**b**), Movat elastic stain, cropped image of a full image scan with magnification approximately equivalent to × 10 objective. Elastic fibers stain black, collagenous fibrous tissue stains green. Note that normal posterior wall contains a thin layer of elastic fibers but mostly is composed of collagen. The hernia sac appears stretched with fragmented elastic layer (color figure online)

as good. Individual surgeons and other registry sources such as Bay-Nielsen (28.7%) [26], Page et al. (75.5%) [27], Poobalan et al. 54% [28], Aasvang et al. (12–55%) [29], Fräneby et al. [30] have confirmed the existence of pain as a serious complication which must require the surgeon's attention rather than the industry.

Most conspicuous among the new pain syndromes are: dysejaculation and sexual pain. Clinical syndromes were

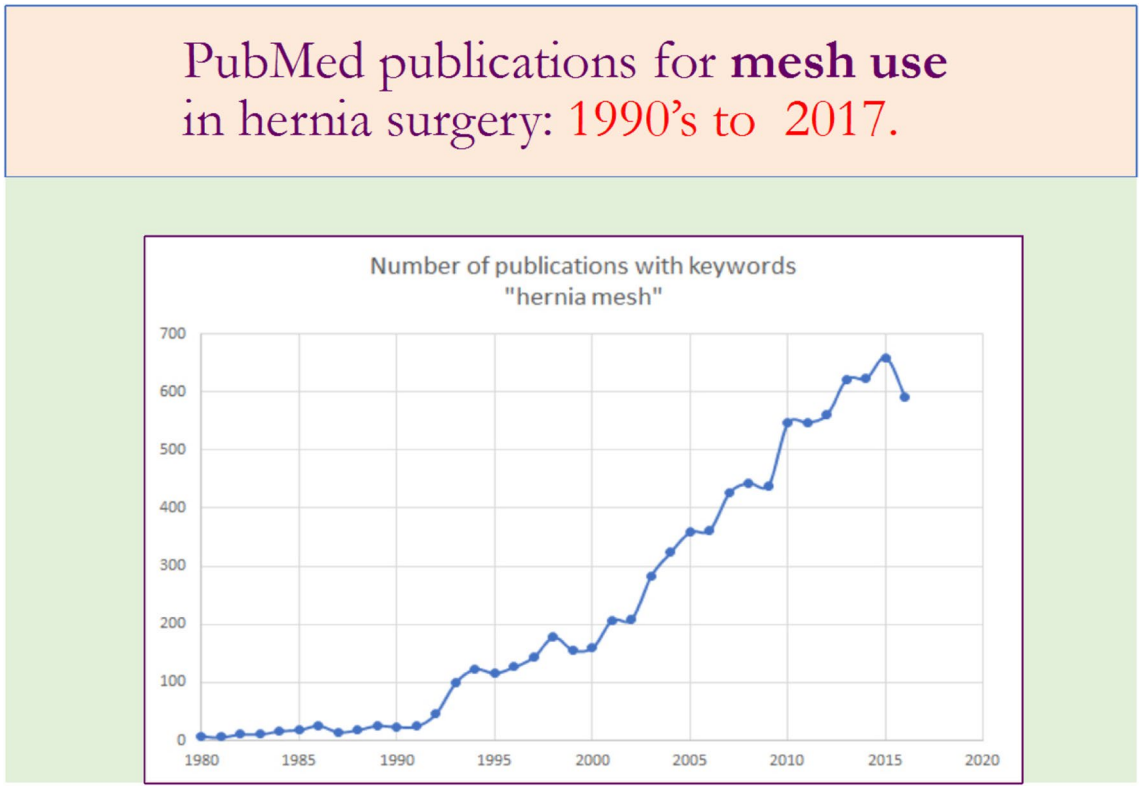

Fig. 3 Sharp escalation in publications on the use of polypropylene mesh which started in the mid-1990s. Francis Usher had presented his work in the mid-1950s but never became popular until the industry began their aggressive campaigns (color figure online). [Courtesy Fernando Carbonell Tatay and SoHAH]

essentially unknown before the introduction of polypropylene mesh. The study by Bischoff et al. provides a salient review with an incidence of chronic inguinodynia of 13%, dysejaculation of 3.1% and pain during sexual activity of 10.9% [13]. When originally reported, before the days of ubiquitous mesh use, dysejaculation had an incidence of 0.04% [31]; this signifies an 80-fold increase in this Swingeing complication!

It is timely again to quote Lloyd M. Nyhus, in 1964, in days when mesh was rarely used: "Every year in the United States some 400,000 inguinal hernias are repaired, and yet even the biggest series of reports of pain after inguino-femoral hernia from the United States are only 17–23 cases. Therefore, this must be a remote hazard of surgery, and as such, patients should not be warned about it" [32].

Joseph Ponka barely mentions pain unless associated with nerve entrapment [33] while Sir Brendan Devlin weighs in, that pain was "never an issue" before the introduction of polypropylene mesh in repairs of abdominal wall hernias [34].

If we are to believe our colleagues, our registries, our guidelines as well as the giant studies and follow-up of The Mayo Clinic and the University of Toronto, we would be looking at a mesh complication rate of dysejaculation of 3.1%, of sexual pain of 10.9%, a recurrence rate of 10% and a rate of chronic post-inguinal herniorrhaphy pain of 13%! A combined minimal rate of 37%! These are the minimum values presented in their publications. Where and what would be the advantage of a mesh repair? With pure tissue repairs, pain could only be secondary to a nerve entrapment, a complication which is unusual if not rare and easily corrected. Besides, nerve entrapment is such a distinct clinical entity that most surgeons would recognize it and correct it within 24–48 h.

We must resist all suggestions and implications that nerves are protected by an investing sheath from being eroded into by mesh. That a good dissection with proper exposure will avoid the attending erosion is but castles in Spain. A colleague, a professor of anatomy, winced when I enquired of such a fascia. He has never heard or seen one. We have reported 13 cases of such gross erosions and in an additional 6 cases, no evidence could be found of vas, cremaster or nerves. So extensive was the erosion and destruction that the content of the inguinal canal was

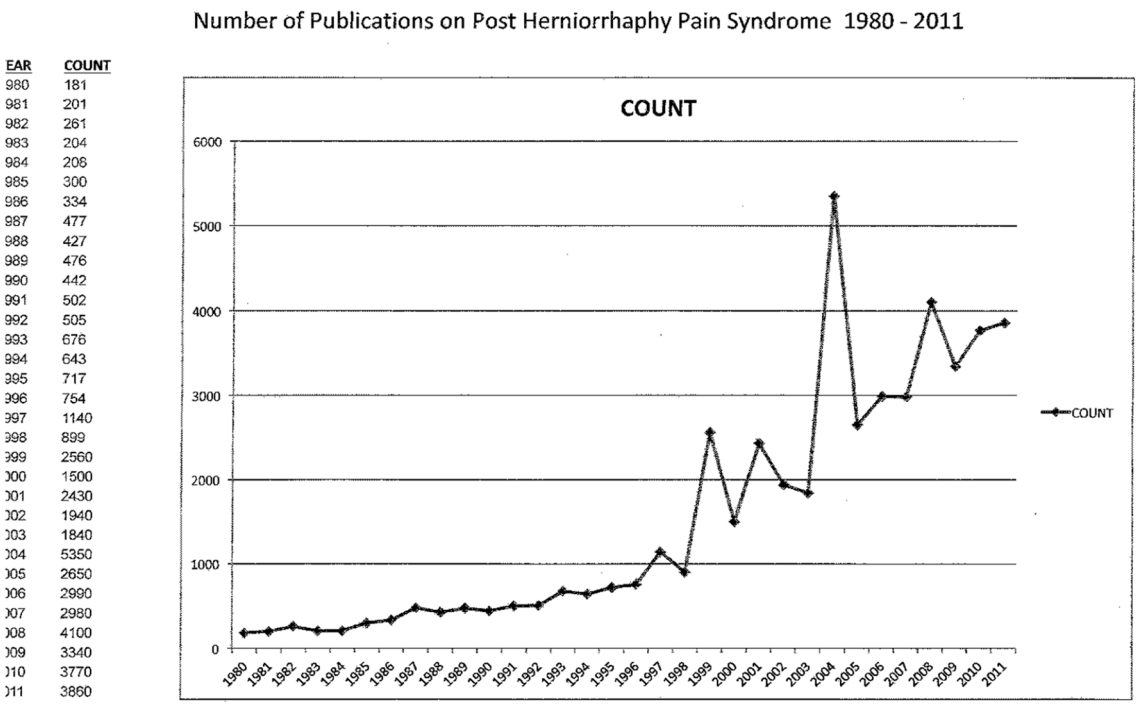

Fig. 4 Sharp and parallel escalation, in time and incidence, in the publication of articles on pain whenever mesh was used. As stated by Nyhus, Ponka and Devlin this complication was rare before mesh use (color figure online). Source: Compiled from Google Scholar. [Courtesy Fernando Carbonell Tatay and SoHAH]

entirely replaced by scar tissue and confirmed by a pathologist [35–37]. Figures 1 and 2 show the clear demarcation of muscles of the posterior inguinal wall from its poor "transversalis fascia" of a direct inguinal hernia; Figs. 3 and 4 demonstrate in a clear ascending curve when post-operative inguinodynia began in parallel with mesh use, both dating back to the mid-1990s. Figures 5 and 6 provide a clear, undeniable illustration of the erosive effect of polypropylene on the vas deferens.

The current Shouldice statistics

While recording data, the Shouldice Hospital has always made a point of recording secondary hernias. These are hernias, smaller in size than the primary ones but whose presence would have required some form of management, on their own. In the series below, covering the same period as the Urbach paper (1993–2007), the incidence of secondary hernias was 15.1%. A figure which has been constant ever since the hospital began keeping data. An old study by Obney and Chan of the Shouldice Hospital, revealed that of 1057 patients referred to them with a recurrence, 37% had a recurrent indirect inguinal hernia thus proving that the previous surgeon did not find the hernia which is now considered a missed hernia and therefore, a bona fide "recurrence" [38].

Statistics of the Shouldice Hospital to cover the years of the Urbach study (Tables 1, 2, 3, 4).

Within that same period, several values were calculated:

Males made up 95.8% of all primary hernias, while female made up 4.2%.
Males made up 95.5% of all secondary hernias, while female made up 4.5%.
Total mesh use over 14 years, 562:80,878 cases or 0.70%.
Total mesh use in males in primary and secondary hernias, 489:76,978 or 0.64%.
Total mesh use in females in primary and secondary hernias, 73:3,892 or 1.88%.

It becomes obvious that there is no rational, nor valid reason for the use of any mesh following an indirect inguinal hernia repair. This means almost half of all Lichtensteins, all plug repairs, plug and patch, PHS, Trabucco plug, Kugel patch. Certainly, wherever needed, if mesh is to be used, none of the devices can be as effective as a plain sheet.

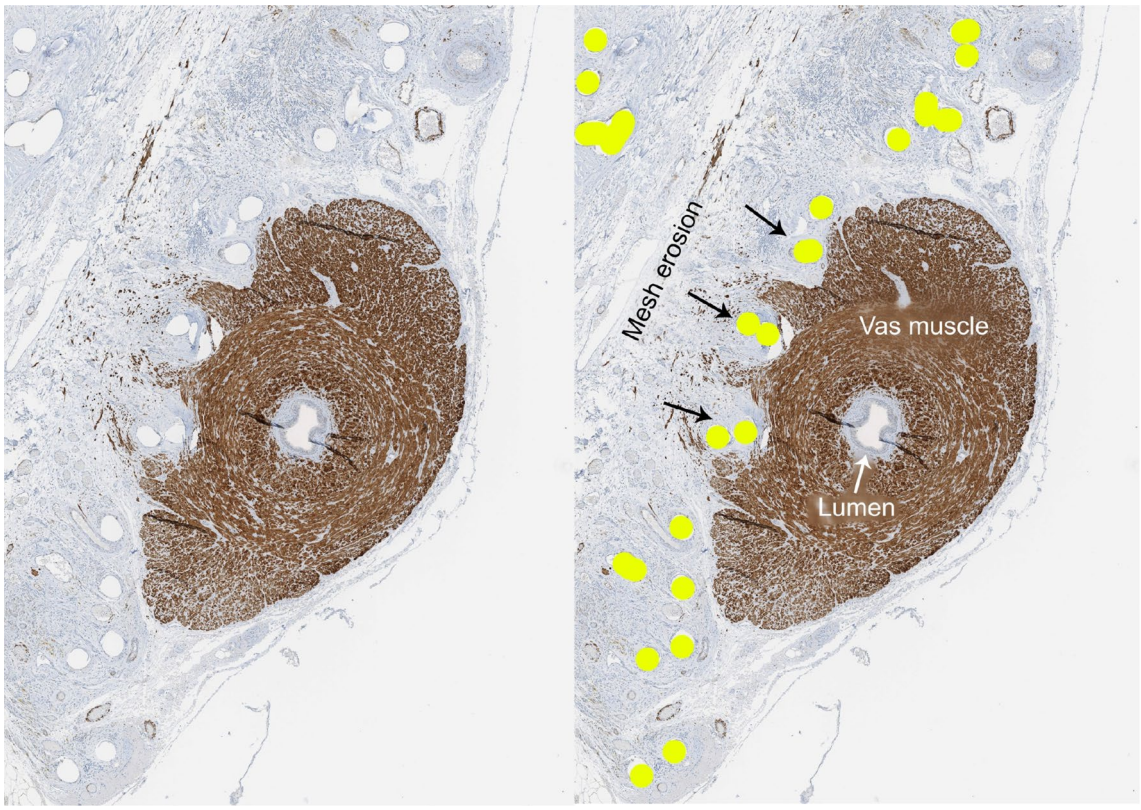

Fig. 5 Evidence of erosion by mesh into the vas deferens. Polypropylene fibers stained yellow to highlight its appearance, leaving a "tooth comb" effect on the vas (color figure online)

Recommendations

For results with the Bassini repair, we should consider his own rate of recurrence rate of (2.87%) as an objective for comparable clinical situations and as reported in his classic diary [39] with no mortality as has been erroneously reported [40]. The multitudinous reports of 20–40% recurrence rates in the past reflected a thorough neglect of a discipline which had no prestige, or failure of the surgeons to appreciate the anatomy/physiology in learning or teaching its finer features or an intent to push one's own envelope by adopting the "newer savvy" techniques with mesh.

For the McVay repair, incidences in the proper hands can be kept under 2%, as reported by Rutledge who was best known for his series of McVay repairs [41].

For the Shouldice repair, as reported by the largest independent study in Ontario, or anywhere, through the government's database of 235,192 patients in a 14-year study, the incidence was 1.15% as reported above in the extensive discussion. In that project, the Shouldice Hospital had never been consulted and the study stands as an objective, unbiased contribution through an organization (ICES) which had no self-interest in the equation and has no fealty towards anyone.

I have consciously omitted the Desarda repair because it specifically does not enter the preperitoneal space. His plication of the posterior wall of the inguinal canal has been the most pernicious and detrimental maneuver ever devised in groin hernia surgery. It has allowed a false sense of security of a wall that seems impervious to pressure when it is not. The failure in plication is due to the fact that pure skeletal muscle is omitted in the repair of the posterior inguinal wall. Plication brings together the degenerative posterior and inferior collagenous, degenerated layers of the posterior inguinal wall.

Though the operation was described in 2001, no long-term studies have been published. In addition, a one-inch strip of external oblique aponeurosis covering the plication of the posterior inguinal wall consists of a layer much subject to herniosis and eventual breakdown. Neither is there an attempt to discover femoral or additional hernias. For indirect inguinal hernias, with a solid posterior inguinal wall, the strip of external oblique aponeurosis becomes a redundant and irrelevant step.

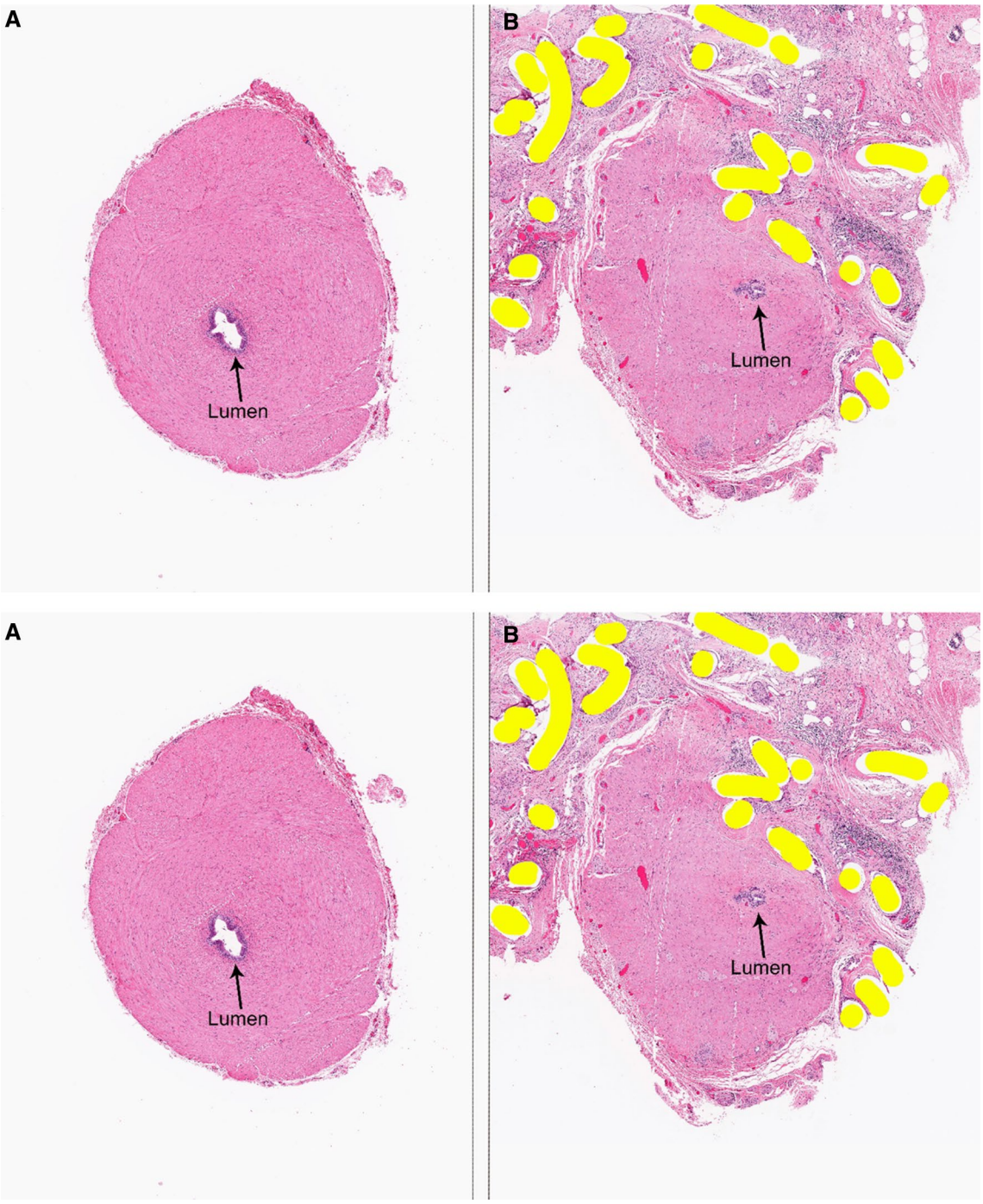

Fig. 6 Comparison of normal vas (**a**, left) and affected by mesh erosion (**b**, right), H&E stain, cropped image of a full image scan with magnification approximately equivalent to × 10 objective. Clear evidence of mesh invasion into the vas. Mesh fibers stained yellow (color figure online)

Conclusion

Polypropylene mesh has been with us long enough for its flaws to manifest themselves, be observed and analyzed. General use did not become widespread until the mid-1990s, undoubtedly stoked by an aggressive industry. It is a fact also that not all patients seem affected adversely within the proposed follow-ups of 3 months or even 6 for complications such as pain and erosion but time is proving to be a crucial factor as demonstrated by Iakovlev et al. [35]. Time lapse for such issues may be as long as 10 years and much more.

Unfortunately, polypropylene meshes have spawned new clinical syndromes such as dysejaculation, sexual pain, chronic post-herniorrhaphy pain in no small way, along with

Table 1 Primary inguinal hernias in males repaired at Shouldice Hospital (1993–2007)

Mesh use	Indirect hernia	Direct hernia	Total
No mesh	48,099	28,676	76,775
Mesh	100	103	203
Totals	48,199	28,779	76,978

Table 2 Primary inguinal hernias in females repaired at Shouldice Hospital (1993–2007)

Mesh use	Indirect hernia	Direct hernia	Total
No mesh	3013	305	3318
Mesh	22	6	28
Totals	3035	311	3346

Table 3 Secondary inguinal hernias in males repaired at Shouldice Hospital (1993–2007)

Mesh use	Indirect hernia	Direct hernia	Total
No mesh	3483	7965	11,448
Mesh	48	92	140
Totals	3531	8057	11,588

Table 4 Secondary inguinal hernias in females repaired at Shouldice Hospital (1993–2007)

Mesh use	Indirect hernia	Direct hernia	Total
No mesh	263	238	501
Mesh	31	14	45
Totals	294	252	546

a surprisingly high recurrence rates, all of which have made this olefin somewhat dubious at best even in the finest of surgical hands.

If indeed the reports of our colleagues in Herniasurge [25], the Danish database [26], meta-analyses, RCTs sum up to a possibility of a third or more of our patients suffering complications, perhaps it is time to reconsider and take stock. How many patients, properly notified, warned, would accept a cumulative risk for a complication as high as 37%?

Looking at the various intricate algorithms to follow, it may simply be much wiser, if one masters a pure tissue technique, to apply it to all patients with primary hernias and save any future recurrences or difficult problems to be managed with mesh.

On this issue, Cicero did not miss the point … "The safety of the people shall be the highest law".

Acknowledgements We would like to thank Mr. Eric Frysberg for his able contribution in all matters of data handling.

Compliance with ethical standards

Conflict of interest No conflict of interest to declare on the part of the participating authors.

Human and animal rights This article does not contain any studies with human participants or animals performed by any of the authors.

Informed consent For this type of study, formal consent is not required.

References

1. Usher F, Cogan JE, Lowry TI (1960) A new technique for the repair of inguinal and incisional hernias. Arch Surg 81:847–854
2. Iason AH (1940) Hernia. The Blakiston Company, Philadelphia, pp 475–604
3. Junge K, Peiper C, Schachtrupp A, Schumpelick V (2003) Breaking strength and tissue elasticity after Shouldice repair. Hernia 7(1):17–20 **(Epub 2003 Jan 15)**
4. Bendavid R (1986) The, "Fletching": a new implant for the treatment of inguino-femoral hernias. Int Surg 71(4):248–251
5. Bendavid R (1987) A femoral umbrella for femoral hernia repair. Surg Gynecol Obstet 65(8):153–156
6. Bendavid R (1997) Composite mesh (polypropylene-e-PTFE) in the intraperitoneal position. A report of 30 cases. Hernia 1:5–8
7. Bendavid R (1992) Prosthetics in hernia surgery. A confirmation. Postgrad Gen Surg 4(2):166–167
8. Bendavid R (1993) A rational use of mesh in hernia. A perspective. Int Surg 77(4):229–231
9. Bendavid R (1994) Prostheses and abdominal wall hernias. RG Landes Company, Austin 9:590
10. Bendavid R, Iakovlev V et al (2016) A mechanism of post-herniorrhaphy neuralgia. Hernia 20(3):357–365
11. Iakovlev V, Bendavid R (2018) A pathology of mesh and time. Ann Surg 267:569–575
12. Bendavid R, Lou W, Koch A, Iakovlev V et al (2014) Mesh-related SIN syndrome. A surreptitious irreversible neuralgia and its morphologic background in the etiology of post-herniorrhaphy pain. Int J Clin Med 5(13):21
13. Bischoff JM, Linderoth G, Aaswang EK, Werner MU, Kehlet H (2012) Dysejaculation after laparoscopic inguinal herniorrhaphy. Surg Endosc 26(4):979–983
14. Skandalakis JE (2004) Surgical anatomy. Paschalidi Publications, Athens
15. Rodrigues AJJR, Rodrigues CH, Terra R, Popler C (1998) Anatomical study of venous architecture at the space of Bogros by preperitoneal approach. In: Department of Surgery, Faculty of Medicine, University of Sao Paolo, Brazil in American Association of Clinical Anatomists, 15th annual meeting
16. Paterson-Brown S, Garden J (1994) Surgical laparoscopy. Cambridge University Press, Cambridge
17. Muller G, Scheyer M, Zimmerman G (1994) Shouldice-Plastik-Erfahrungen. Acta Chir Austriaca 23(Suppl 110):9
18. Junge K, Peiper C, Rosch R, Lynen P, Schumpelick V (2002) Effect of tension induced by Shouldice repair on postoperative course and long-term outcome. Eur J Surg 168(6):329–333. https://doi.org/10.1080/11024150260284824

19. Peiper C, Junge K, Füting A, Bassalaý P, Conze J, Schumpelick V (2001) Inguinal tensile strength and pain level after Shouldice repair. Hernia 5(3):129–134
20. Schippers E, Peiper C, Schumpelick V (1996) Pro-Shouldice: primary tension-free hernia repair—conditio sine qua non? Swiss Surg 4:33–36
21. Murphy BL, Ubl DS, Paley K et al (2018) Trends of inguinal hernia repairs performed for recurrence in the United States. Surgery 163(2):343–350. https://doi.org/10.1016/j.surg.2017.08.001 **(Epub 2017 Sep 15)**
22. Malik A, Bell CM, Stukel TA, Urbach DR (2016) Recurrence of inguinal hernias repaired in a large hernia surgical specialty hospital and general hospitals in Ontario. Can J Surg 59(1):19
23. Ramjist JK, Dossa F, Stukel TA, Urbach DR, Fu L, Baxter NN (2018) Reoperation for inguinal hernia recurrence in Ontario: a population-based study. Hernia. https://doi.org/10.1007/s10029-018-1822-0 **(Epub ahead of print)**
24. Fruchaud H (1956) Anatomie chirurgicale des hernies de l'aine chez. DOIN, Paris
25. The HerniaSurge Group (2018) International guidelines for groin hernia management. Hernia 22(1):1–165
26. Bay-Nielsen M, Perkins FM, Kehlet H, Danish Hernia Database (2001) Pain and functional impairment 1 year after inguinal herniorrhaphy: a nationwide questionnaire study. Ann Surg 233(1):1–7
27. Page B, Paterson C, Young D, O'Dwyer PJ (2002) Pain from primary inguinal hernia and the effect of repair on pain. Br J Surg 89(6):809
28. Poobalan AS, Bruce J, Smith WC, King PM, Krukowski ZH, Chambers WA (2003) A review of chronic pain after inguinal herniorrhaphy. Clin J Pain 19(1):48–54 **(PMID:12514456)**
29. Aasvang E, Kehlet H (2005) Chronic postoperative pain: the case of inguinal herniorrhaphy. Br J Anaesth 95(1):69–76 **(Epub 2004 Nov 5)**
30. Fränneby U, Sandblom G, Nordin P et al (2006) Risk factors for long-term pain after hernia surgery. Ann Surg 244(2):212–219
31. Bendavid R (1992) "Dysejaculation": an unusual complication of inguinal herniorrhaphy. Postgrad Gen Surg 4(2):1992
32. Nyhus LM (1995) Hernia, 4th edn. Lippincott, Philadelphia, p 215
33. Joseph P (1980) Hernias of the abdominal wall. WB Saunders Co, Philadelphia
34. Devlin HB (1995) Chronic pain after hernia repair. Expert meeting on hernia surgery. Basel-Karger Publication, St Moritz, pp 365–367
35. Iakovlev V, Koch A, Petersen K, Morrison J, Grischkan D, Oprea V, Bendavid R (2018) A pathology of mesh and time. Dysejaculation, sexual pain, and orchialgia resulting from polypropylene mesh erosion into the spermatic cord. Ann Surg 267(3):569
36. Nguyen DK, Amid PK, Chen DC (2016) Groin pain after inguinal hernia repair. Adv Surg 50:203–220
37. Alfieri S, Amid PK, Campanelli G et al (2011) International guidelines for prevention and management of post-operative chronic pain following inguinal hernia surgery. Hernia 15:239–249. https://doi.org/10.1007/s10029-011-0798-9
38. Obney N, Chan CK (1984) Repair of multiple time recurrent inguinal hernias with reference to common causes of recurrence. Contemp Surg 25:25
39. Bassini E (1889) Nuovo Metodo Operativo per la Cura Dell'Hernia Inguinale. R. Stabilimento Prosperini, Padova
40. Ramshaw B, Jacob BP (2013) Sages manual of hernia repair. Sages, Russell
41. Ryan John J (2001) The McVay operation in abdominal wall hernias: principles and management. Springer, New York, pp 365–369